

inhibitors, commonly used to lower blood pressure or treat heart failure. These medications have shown an improvement in CSCR symptoms for some patients, although other studies have not shown benefit. Further studies are currently being carried out to evaluate the role of these treatments. When on this treatment, these drugs may cause side effects in some patients including changing the salt (potassium) level in the blood which will need monitoring. Other potential side effects which vary by drug will be discussed by your doctor during the clinic consultation.

HOW CAN I GET TREATMENT?

As mentioned previously, all the above treatments listed are not licensed or NICE approved for managing CSCR. This means your eye doctor may need to try and get funding for treatment and the success of this depends on your local health authority funding budget. This situation can often lead to delays in treatment or in some cases it is not possible to get funding for a recommended treatment. The funding situation is currently subject to change and you will need to discuss this further with your eye doctor.

CAN CHANGING GLASSES HELP MANAGE CSCR?

Changing existing glasses or getting new glasses does not help manage CSCR, as your glasses prescription can be different depending on the amount of retinal fluid you have. Changing your glasses prescription would only help temporarily; therefore, it is advisable to wait until the retinal fluid has been completely resolved.



PLEASE SCAN FOR
THE LOCATION

Aster
HOSPITAL
We'll Treat You Well

Mankhool, Kuwait Road, Al Mankhool - Dubai

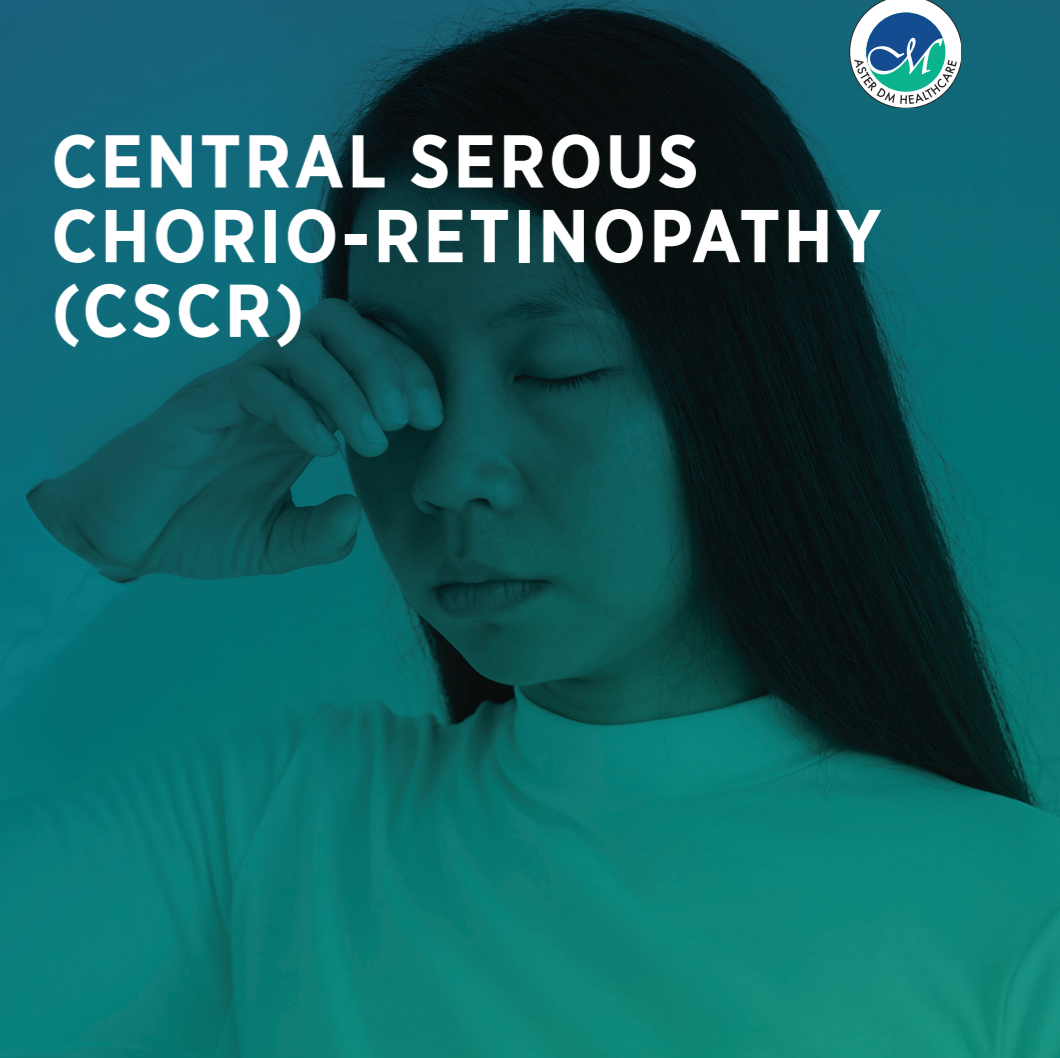
☎ 04 440 0500 🌐 asterhospitals.com 📱 📺 📷 asterhospital

Aster
HOSPITAL
We'll Treat You Well

DEPARTMENTS

Accident & Emergency • Anesthesiology • Cardiology • Clinical Nutrition
Dental Centre • Dermatology • ENT • General Surgery • Insurance
Internal Medicine • Laboratory Services • Neurosurgery • Ophthalmology
Obstetrics & Gynaecology • Orthopedics • Patient Affairs

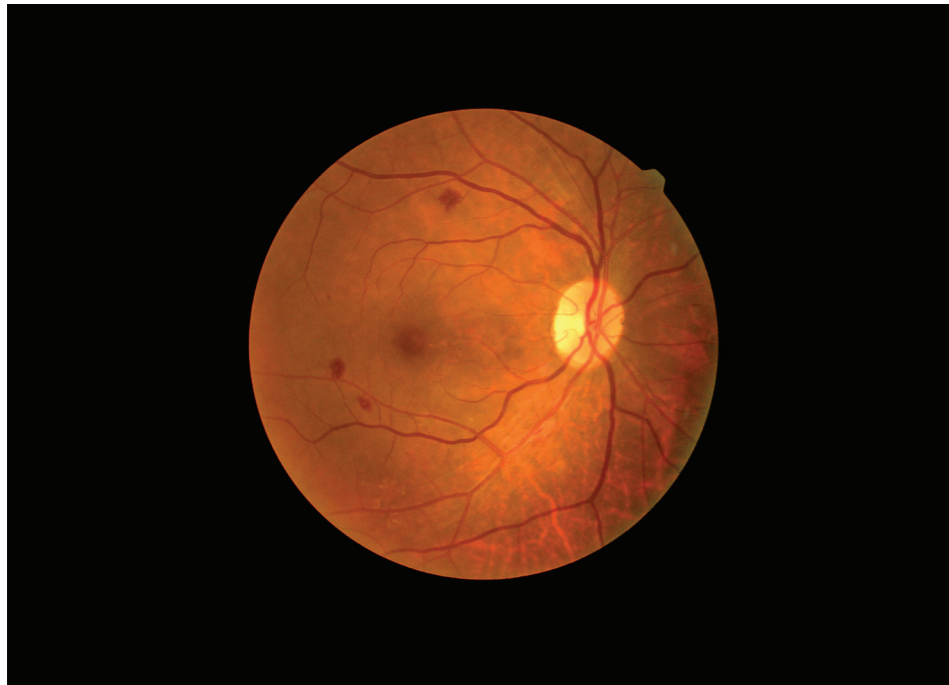
CENTRAL SEROUS CHORIO-RETINOPATHY (CSCR)



Aster
HOSPITAL
We'll Treat You Well

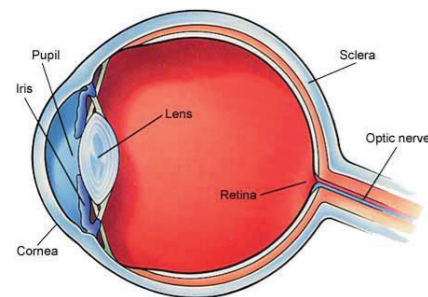


Digital Version



Central serous chorio-retinopathy(CSCR) is a condition that affects the retina the light sensitive tissue that lines the back of the eye.

DIAGRAM OF THE EYE



Central serous chorio-retinopathy (CSCR), refers to a collection of fluid under the retina. This is caused by a disturbance in the pumping action of special cells called

RPE cells (retinal pigment epithelial cells) and/or abnormalities in the vascular (blood vessel) layer, known as choroid. RPE cell layer and blood vessel layer (choroid) line the outer surface of retina and both layers function to keep the retina healthy. This dysfunction results in fluid leakage under the retina in a bubble-like swelling called central serous chorio-retinopathy (CSCR).

WHAT ARE THE SYMPTOMS OF CSCR?

CSCR usually affects those between 30 to 50 years of age. Males are more likely to be affected than females. Main symptoms include:

- painless blurriness of central vision.
- distortion or a change in size of an object.
- straight objects or lines seeming curved (distorted).

- difficulty in reading small prints with the affected eye.
 - some patients notice that they need to change reading glasses more often.
- In most cases, the symptoms only last for a few months; however it may last longer in a minority of patients, potentially leading to a long-term worsening of vision.

WHAT CAUSES CSCR?

The exact factors that cause the development of CSCR related fluid have not yet been determined. However, we know of various risk factors that are associated with the development of CSCR.

1) Steroids

Steroids are a known risk factor for the development of CSCR. These include steroids in different forms such as inhalers for asthma, nasal spray for hay fever, steroid cream for eczema and steroid tablets such as prednisolone.

Rarely, in a condition (known as Cushing syndrome), an over production of the body's natural steroid hormone could lead to the development of CSCR.

2) Stress

A major stressful event, either work-related or personal, is believed to trigger the development of CSCR in some patients.

3) Psychological make-up

Research has shown that certain personality types (particularly those who are hard-driven and competitive), are more at risk of developing this condition.

4) Genetic risk

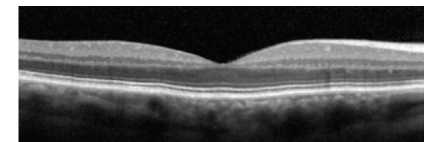
There are ongoing studies suggesting some patients may have changes in certain genes that can trigger CSCR when exposed to certain environmental factors.

HOW IS CSCR DIAGNOSED?

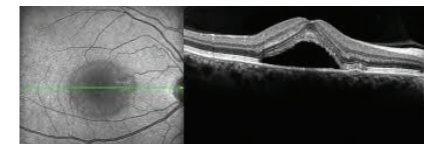Generally, the diagnosis is made by taking your detailed history which includes medical and drug history, clinical examination of eyes and imaging tests.

TYPES OF IMAGING TESTS:

1) Optical coherence tomography (OCT) is a scan of the retina. It is a non-invasive camera-based imaging test which uses light waves to take cross-section pictures of your retina; It is used to identify the fluid under the retina, along with detailed structural changes secondary to CSCR. This imaging tool is not only useful in making a diagnosis but is also helpful in monitoring your condition. Some forms of OCT (OCT- angiography) look at abnormal blood vessel growth that can rarely complicate CSCR. Your consulting eye doctor will decide whether this test is needed.



Normal retina on OCT imaging



OCT image showing retinal fluid in CSCR

2) FFA and ICG test (Fundus fluorescein angiography (FFA) and Indocyanine green angiography (ICG))

i.e. dye contrast photographs of the retina. During this test a coloured dye is injected into your arm, followed by a series of photographs taken of your retina using a special camera. This test helps to identify the leaking area in your retina. The information found

through these investigations will help to develop your individual treatment plan and rule out other similar conditions if the findings are unusual. Not everyone requires this test and your consulting eye doctor will decide whether this test is needed.

WHAT ARE THE COMPLICATIONS OF CSCR?

A small percentage of patients develop a growth of abnormal blood vessels under the retina (called choroidal neovascular membrane-CNVM), which leaks fluid in the retina. This membrane (CNVM) can be spotted by having an angiography of the eye (FFA/ICG) or special retinal scan (OCT-angiography) and can be treated with anti-VEGF injections in the eye.

Some patients with long-term CSCR develop loss of function of special retinal cells called " RPE cells (retinal pigment epithelial). This results in a permanent worsening of vision.

HOW IS CSCR TREATED?

Observation

In most cases (85%), the fluid in the retina settles on its own within one-six months and needs no specific treatment. Any known possible triggers such as corticosteroid use should be reviewed and stopped if this is medically appropriate. Any other medical conditions that can act as a trigger should also be treated.

However, in a small number of patients, the condition can last longer than four-six months. Some patients may experience frequent flare ups, leading to a gradual worsening of their vision. In these cases, treatment may need to be considered.

Active treatment

As of 2018, there is no licensed or NICE approved (National Institute for Health and Care Excellence) treatment for this condition. However, there are various treatment options available that have some evidence to support that they work in managing CSCR. Research is currently being carried out to discover new types of treatment. The treatments may reduce or resolve the fluid collection under the retina but cannot restore damaged cells in the retina.

CSCR TREATMENT OPTIONS:

1. Photo dynamic therapy (PDT)

PDT is a form of 'cold laser' treatment, using non-toxic light sensitive dye. The dye molecules are triggered by infrared light which stops the leakage of fluid in the retina. This results in removing the retinal fluid in about 80% of eyes with one to two treatment sessions, with a reduction in symptoms of distortion and improvement of vision. However, it has also been found that not all patients get their vision back, despite the retinal fluid being removed. This procedure does carry some risks (estimated 1% risk of vision loss) and not everyone is suitable for the treatment.

2. Conventional laser: If the source of the retinal fluid associated with CSCR is away from the central macula then this treatment option may be considered.

3. Micro-pulse laser: This is a sub-threshold (low -power) laser which is applied in short pulses to the area of leakage, resulting in fixing the retinal fluid. Recent studies have shown that this treatment is inferior to PDT.

4. Oral medications: There are some recent studies that have shown the effectiveness of certain tablets in reducing the fluid in CSCR. Eplerenone and Spironolactone are mineralocorticoid